

Impact Factor: 5.186

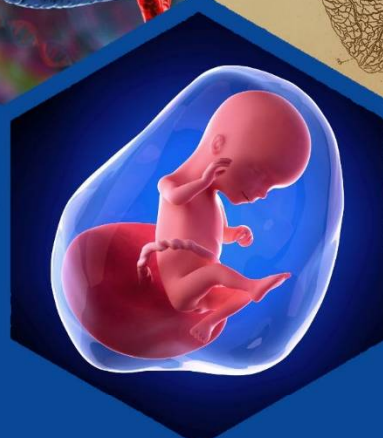
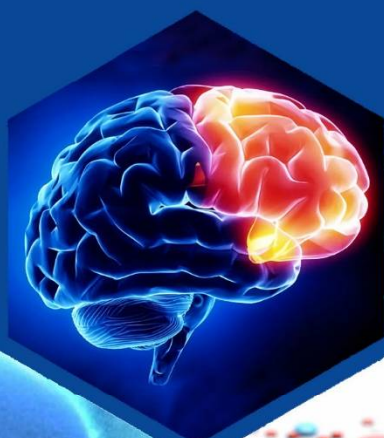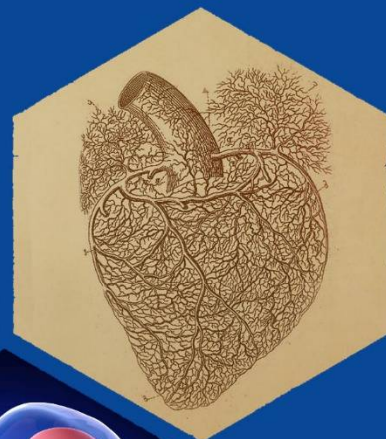
ISSN: 2181-0664

DOI: 10.26739/2181-0664

www.tadqiqot.uz

UZBEK MEDICAL JOURNAL

Special Issue 1



2023



ISSN 2181-0664

Doi Journal 10.26739/2181-0664

ЎЗБЕК ТИББИЁТ ЖУРНАЛИ

1 МАХСУС СОН

УЗБЕКСКИЙ МЕДИЦИНСКИЙ ЖУРНАЛ
СПЕЦИАЛЬНЫЙ НОМЕР 1

UZBEK MEDICAL JOURNAL
SPECIAL ISSUE 1



ТОШКЕНТ-2023

ЎЗБЕК ТИББИЁТ ЖУРНАЛИ

ЎЗБЕКСКИЙ МЕДИЦИНСКИЙ ЖУРНАЛ | UZBEK MEDICAL JOURNAL

№SI-1 (2023) DOI <http://dx.doi.org/10.26739/2181-0664-2023-SI-1>

Бош мухаррир:
Главный редактор:
Chief Editor:

Мадазимов Мадамин Муминович
Ректор Андижанского Государственного
медицинского института, д.м.н., профессор
кафедры факультетской и госпитальной
хирургии

Тахририят раиси:
Председатель редакционной коллегии:
Chairman of the editorial Board:

Алексеев Андрей Анатольевич
Директор ожогового центра НМИЦ хирургии
им. В.Вишневского, главный комбустиолог
Министерства здравоохранения России, д.м.н.,
профессор.

Бош мухаррир ўринбосари:
Заместитель главного редактора:
Deputy Chief Editor:

Салахиддинов Камалиддин Зухриддинович
доцент, д.м.н. кафедры факультетской и
госпитальной хирургии Андижанского
Государственного медицинского института

Бош мухаррир ўринбосари:
Заместитель главного редактора:
Deputy Chief Editor:

Хегай Любовь Николаевна
доцент, к.м.н., начальник отдела по координации
деятельности грантов Межвузовской научно-
исследовательской лаборатории Ташкентской
медицинской академии

Маъсул котиб:
Ответственный секретарь:
Executive Secretary:

Досина Маргарита Олеговна
в.н.с. ГНУ "Институт физиологии Национальной
академии наук Беларуси", к.б.н., председатель
Совета молодых ученых Отделения медицинских
наук НАН Беларуси

Маъсул котиб:
Ответственный секретарь:
Executive Secretary:

Ниязова Зебинисо Анваровна
PhD кафедры офтальмологии, детской
офтальмологии Ташкентского педиатрического
медицинского института

ЎЗБЕК ТИББИЁТ ЖУРНАЛИ ТАХРИРИЙ МАСЛАХАТ КЕНГАШИ | РЕДАКЦИОННЫЙ СОВЕТ ЎЗБЕКСКИЙ МЕДИЦИНСКИЙ ЖУРНАЛ EDITORIAL BOARD OF THE UZBEK MEDICAL JOURNAL

Хужамбердиев Мамазоир Ахмедович

д.м.н., профессор кафедры госпитальной терапии Андижанского Государственного медицинского института

Привалова Ирина Леонидовна

д.б.н., профессор кафедры нормальной физиологии Курского государственного медицинского университета,
заведующая лабораторией физиологии висцеральных систем НИИ физиологии (Курск)

Гаврилова Елена Анатольевна

д.м.н., профессор, заведующая кафедрой лечебной физкультуры и спортивной медицины Северо-западного
государственного медицинского университета им. И.И. Мечникова (Санкт-Петербург)

Чурганов Олег Анатольевич

д.п.н., профессор кафедры ЛФК и спортивной медицины Северо-Западного государственного
медицинского университета им. И.И. Мечникова (Санкт-Петербург)

Салахиддинов Зухриддин Салахиддинович

д.м.н., профессор, заведующий кафедрой ВОП №1, Андижанского государственного медицинского института

Рябчиков Денис Анатольевич

д.м.н., в.н.с. онкологического отделения хирургических методов лечения ФГБУ "НМИЦ
онкологии им. Н.Н. Блохина" Минздрава России

Гулямов Суръат Саидвалиевич

д.м.н., профессор кафедры оториноларингологии, детской оториноларингологии, стоматологии
Ташкентского педиатрического медицинского института

Тереза Магалхайз
профессор, заведующая кафедрой Судебной медицины государственного университета Порту (Португалия)

Юлдашев Илхом Рузиевич
д.м.н., профессор, заведующий кафедрой Аллергологии, иммунологии, микробиологии
Ташкентского педиатрического медицинского института

Хамраев Абдурашид Журакулович
д.м.н., профессор кафедры госпитальной детской хирургии, Ташкентского педиатрического медицинского института

РЕДАКЦИОННАЯ КОЛЛЕГИЯ:

Эрматов Низом Жумакулович
д.м.н., доцент, заведующий кафедрой гигиены детей и подростков и гигиены питания Ташкентской медицинской академии

Рузиев Шерзод Ибодуллаевич
д.м.н., доцент кафедры судебной медицины и медицинского права Ташкентского педиатрического медицинского института

Якубова Олтиной Абдуганиевна
доктор медицинских наук, доцент, заведующая кафедрой акушерства и гинекологии, неонатологии факультета повышения квалификации и переподготовки врачей Андижанского государственного медицинского института

Бабич Светлана Михайловна
доцент, заведующая кафедрой социальной гигиены Андижанского государственного медицинского института

Сабирова Рихси Абдукадировна
д.м.н., профессор кафедры медицинской и биологической химии Ташкентской медицинской академии

Цеомашко Наталья Евгеньевна
д.б.н., с.н.с., заведующая отделом медико-генетических исследований МНИЛ Ташкентской медицинской академии

Хамраева Лола Салимовна
доцент, к.м.н. кафедры офтальмологии, детской офтальмологии Ташкентского педиатрического медицинского института

Усманходжаева Адиба Амирсaidовна
доцент, к.м.н., заведующая кафедрой Народной медицины, реабилитологии и физической культуры Ташкентской медицинской академии

Тухтаева Нигора Хасановна
DSc, доцент кафедры пропедевтики внутренних болезней № 2, Ташкентской медицинской академии.

Шарипова Фарида Камилевна
к.м.н., доцент кафедры психиатрии, наркологии и детской психиатрии, медицинской психологии, психотерапии
Ташкентского педиатрического медицинского института

Бузруков Батир Тулкунович
д.м.н., профессор, заведующий кафедрой офтальмологии, детской офтальмологии Ташкентского педиатрического
медицинского института

Туйчиев Галибжан Урмонжонович
к.м.н., доцент, заведующий кафедрой детской хирургии, детской анестезиологии-реаниматологии с курсом
офтальмологии и стоматологии факультета усовершенствования и переподготовки врачей АГМИ

Маматхужаева Гулнора Нажмитдиновна
доцент, к.м.н. кафедры Офтальмологии Андижанского Государственного медицинского института

Каримова Зиёда Кушбаевна
доцент, к.м.н. кафедры Аллергологии, клинической иммунологии, микробиологии Ташкентского педиатрического
медицинского института

Саидходжаева Саида Набиевна
доцент, Phd кафедры неврологии, детской неврологии и медицинской генетики Ташкентского педиатрического
медицинского института

Зуфарова Зухра Хабибуллаевна
доцент, к.ф.н. кафедры промышленной технологии лекарственных средств Ташкентского фармацевтического института

Ибрагимова Марина Фёдоровна
PhD, ассистент кафедры N1 педиатрии и неонатологии Самаркандского государственного медицинского университета.

Алимова Дурдона Дильмуратовна
PhD кафедры оториноларингологии, детской оториноларингологии, детской стоматологии Ташкентского педиатрического
медицинского института

Page Maker | Верстка | Саҳифаловчи: Хўршид Мирзахмедов

Контакт редакций журналов. www.tadqiqot.uz
ООО Tadqiqot город Ташкент,
улица Амира Темура пр.1, дом-2.
Web: <http://www.tadqiqot.uz/>; Email: info@tadqiqot.uz
Тел: (+998-94) 404-0000

Editorial staff of the journals of www.tadqiqot.uz
Tadqiqot LLC the city of Tashkent,
Amir Temur Street pr.1, House 2.
Web: <http://www.tadqiqot.uz/>; Email: info@tadqiqot.uz
Phone: (+998-94) 404-0000


1. Primov F.Sh., Akilov B.B., Kurbonov J.R., Djuraev J.A. EVOLUTION OF VIEWS AND MODERN TRENDS IN ENDOVISUAL SURGICAL TREATMENT FOR URGENT ABDOMINAL PATHOLOGY IN CHILDREN.....	7
2. Pulatova Sh.Kh. A NEW APPROACH TO THE TREATMENT OF TYPE 2 DIABETES MELLITUS WITH CORONARY HEART DISEASE.....	14
3. Pulatova Sh.Kh., Tasheva F.A. A NEW APPROACH TO THE TREATMENT OF DIABETIC NEPHROPATHY WITH HEART FAILURE.....	20
4. Khamroev E.E., Pulatova Sh.Kh. THE CHOICE OF MEDICINAL PRODUCTS FOR CHRONIC HEART FAILURE OF VARIOUS GENESIS IN THE ELDERLY.....	26
5. Rasulova Nodira Alisherovna, Khojaeva Nikzan Nazarbekovna INFLUENCE OF 25(OH)D ON THE CAUSES OF RICKETS IN CHILDREN.....	34
6. Natalya Vladimirovna Voronina, Matluba Shamtsudinova SANITARY AND HYGIENIC MONITORING OF PESTICIDE POLLUTION OF FOOD PRODUCTS IN UZBEKISTAN.....	39
7. Rasulova Nadira Alisherovna, Khakimova Sohiba Ziyadullayevna THE USE OF MUSIC THERAPY FOR THE CORRECTION OF PSYCHOSOMATIC DISORDERS IN CHILDREN.....	46
8. Abdieva Yulduz Atakulovna, Agzamova Gulnara Sunnatovna CHANGES IN THE CYTOKINE PROFILE IN PATIENTS WITH SILICOSIS IN COMBINATION WITH CORONARY HEART DISEASE AND ARTERIAL HYPERTENSION.....	50
9. Davlatova Dilrabo, Usmanova Shoirra THE ROLE OF ENDOTHELIAL DYSFUNCTION IN THE PATHOGENESIS OF INFLAMMATORY PERIODONTAL DISEASES.....	57
10. Nozima Tokhirzhonovna Mavlyanova, Nazifa Valievna Agzamova CLINICAL AND ECONOMIC ANALYSIS AND ITS POSSIBILITIES IN THE EVALUATION OF THE USE OF ANTIBACTERIAL DRUGS.....	64
11. Kamilov Khaydar, Usmanova Lazzat, Akhmadaliev N.N. DYNAMICS OF THE CYTOKINE PROFILE OF THE ORAL FLUID IN PATIENTS WITH SETTON'S APHTHOSIS.....	67
12. Mirzaev Husanjon, Rizaev Eler FEATURES OF THE CLINICAL COURSE AND FREQUENCY OF OCCURRENCE OF PERIODONTAL DISEASES AND ORAL MUCOSA IN PATIENTS SUFFERING FROM CHRONIC KIDNEY DISEASE.....	73

13. Mirzaev Husanjon, Rizaev Eler THE NATURE OF CHANGES IN BIOMARKERS OF KIDNEY DAMAGE IN SALIVA, BLOOD AND URINE IN PATIENTS WITH CHRONIC GENERALIZED PERIODONTITIS....	79
14. Davlatova Dilrabo, Usmanova Shaira ENDOTHELIAL CELL DYSFUNCTION BY CHRONIC GENERALIZED PERIODONTITIS IN PATIENTS WITH ARTERIAL HYPERTENSION.....	85
15. Kamilov Kh.P., Kahharova D.J. HUMAN PAPILLOMA VIRUS AND ORAL MUCOSA LESIONS: INCREASED POTENTIAL OF MALIGNANT DEGENERATION.....	89
16. Rasulov A.B., Arifov S.S., Zufarov A.A. ON THE ISSUE OF HEARING SCREENING AMONG PREMATURE NEWBORNS.....	94
17. Yusupova Shahnoza EFFICIENCY OF IMIQUIMOD IN TREATMENT OF CONDYLOMA ACUMINATA.....	100



Yusupova Shahnoza
Tashkent medical academy
shahnoza.yusupova90@gmail.com

EFFICIENCY OF IMIQUIMOD IN TREATMENT OF CONDYLOMA ACUMINATA

 <http://dx.doi.org/10.5281/zenodo.7828234>

ABSTRACT

Human papillomavirus (HPV) anogenital infections are the most prevalent viral sexually transmitted disease (STD) among young people worldwide. Treatments that have demonstrated good to moderate efficacy in eliminating genital warts include patient-applied topical medications (podophyllotoxin, interferon (IFN)), as well as ablative or cytoreductive techniques. Recurrence rate of condyloma acuminata are an issue, study was performed to evaluate better therapy. How laser treatment for external anogenital warts affected the continued clearance of treated lesions and the safety of topical Imiquimod used by the patient. Asses 2 type of treatment: monotherapy by laser with combined therapy - after laser treatment of visible external anogenital warts, the ablated region(s) were treated with Imiquimod 5% cream, in the following order: three times per week over the course of 12 weeks, starting once when the wound healing process was considered complete, followed by a six-month observation period for the assessment of sustained clearance of treated lesions. 28 (37.3%) of the patients in the first group experienced relapses during the course of the study, according to a correlative assessment of the clinical competence of the treatment. The recurrence rate within 6 months was only 9 (7.2%) and clinical recovery without a recurrence was 116 (92.8%) in group II patients, which is a statistically significant ($p \leq 0.05$) reduction in the relapse rate with the complex method therapy.

Keywords: condylomata acuminata, immune response modifier, recurrences, monotherapy, genital warts, Human papillomavirus, viral infections, cellular immune.

Юсупова Шахноза

Ташкентская медицинская академия
shahnoza.yusupova90@gmail.com

ЭФФЕКТИВНОСТЬ ИМИКВИМОДА ПРИ ЛЕЧЕНИИ ОСТРОКОНЕЧНЫХ КОНДИЛОМ

АННОТАЦИЯ

Остроконечные кондиломы, вызванные вирусом папилломы человека (ВПЧ), являются наиболее распространенным вирусным заболеванием, передающимся половым путем (ЗППП) среди молодежи во всем мире. Разные виды терапии демонстрируют хорошую или умеренную эффективность в устранении генитальных бородавок, куда входит нанесение пациентами местных препаратов (подофиллотоксин, интерферон (ИФН)), а также абляционные или цитодеструктивные методы. В настоящее время частота рецидивов остроконечных кондилом

является одной из актуальных проблем. Данное исследование было проведено для оценки сравнительной эффективности двух методов терапии: монотерапию лазером сравнивали с комбинированной терапией - после лазерного лечения видимых наружных аногенитальных бородавок область абляции обрабатывали кремом Имиквимод 5% в следующем порядке: 3 раза в неделю курсом 12 недель, с последующим шестимесячным периодом. У 28 (37,3%) больных I-й группы в ходе исследования развились рецидивы. Частота рецидивов в течение 6 мес составила всего 9 (7,2%) и клиническое выздоровление без рецидивов — 116 (92,8%) у больных II группы, что является статистически значимым ($p \leq 0,05$) снижением частоты рецидивов при комбинированном методе терапии.

Ключевые слова: остроконечные кондиломы, модификатор иммунного ответа, рецидивы, монотерапия, генитальные бородавки, вирус папилломы человека, вирусные инфекции, клеточный иммунитет.

Yusupova Shahnoza

Toshkent tibbiyot akademiyasi
shahnoza.yusupova90@gmail.com

O'TKIR UCHLI KONDILOMALARDA IMIKVIMOD KREMINI SAMARADORLIGI

ANNOTASIYA

O'tkir uchli kondilomalar odam papilloma virusi keltirib chiqaradigan, jinsiy yo'l orqali yuquvchi kasallikdir va dunyo bo'ylab yoshlar orasida keng tarqalgan. Davolashda qo'llaniladigan mahalliy dorilar (podoksilifilin, interferon) va sitodestruktiv usullar o'rtacha samaradorlikni ko'rsatmoqda va qaytalanish darajasi yuqori bo'lib qolmoqda. Ushbu tadqiqotda ikkita davolash usulini taqqoslash uchun monoterapiyani lazer yordamida o'tkir uchli kondilomalarni olib tashlab, kompleks davo uchun anogenital so'gallar olingan joyiga 12 hafta davomida 5% Imikvimod kremi surtish tavsiya qilingan. 6 oylik kuzatuv natijasida 1-guruhdagi 28 (37,3%) nafar bemorlarda qaytalanishlar kuzatilgan. 2-guruh bemorlarda 6 oy ichida qaytalanish chastotasi faqat 9 ta (7,2%) bo'lgan va klinik yahshilanish 116 (92,8%) tani tashkil qilgan.

Kalit so'zlar: o'tkir uchli kondiloma, TLR retseptorlar, qaytalanish chastotasi. monoterapiya, inson papillomavirusi, virusli infektsiyalar, hujayra immuniteti.

Introduction.

Human papillomavirus (HPV) anogenital infections are the most prevalent viral sexually transmitted disease (STD) among young people worldwide [1]. Treatments that have demonstrated good to moderate efficacy in eliminating genital warts include patient-applied topical medications (podophyllotoxin, interferon (IFN)), as well as ablative or cytoreductive techniques [1,2]. Due to anesthesia or many therapeutic interventions required to completely eliminate the wart region, the majority of ablative therapy techniques have the potential to be uncomfortable and painful for the patient. Yet, the high rate of wart recurrences after effective first treatment is thought to be the most source of frustration. The recorded recurrence rates for ablative techniques range from 20% with surgical excision to 50% with alternative destructive therapies. The lack of antiviral action with the majority of the suggested therapy is one theory for the recurrent recurrence of warts. As a result, only the wart itself is physically eliminated, leaving the surrounding tissue still harboring latent HPV that could reactivate [3,4].

Since Imiquimod is known to generate many subtypes of IFN- α and IFN- γ as well as a variety of cytokines linked to Th1-cell-mediated immunity, it is a more comprehensive and natural approach. The first member of a novel class of immune response modifiers with significant antiviral and anticancer action is Imiquimod, an imidazoquinolinamine derivative [5,6]. It has been demonstrated that Imiquimod 5% cream, used three times per week for a maximum of 16 weeks, is both extremely effective and secure for use in the primary treatment of external genital warts [7-9]. In one research, with three weekly doses and a 12-week treatment-free follow-up period, the recurrence rate was as

low as 13% [8]. Recurrence rates following wart ablation may be lowered by adjuvant IFN therapy, which would also improve the patient's resistance to viral infections. The majority of study findings, however, did not consistently demonstrate the advantages of combination therapy [10].

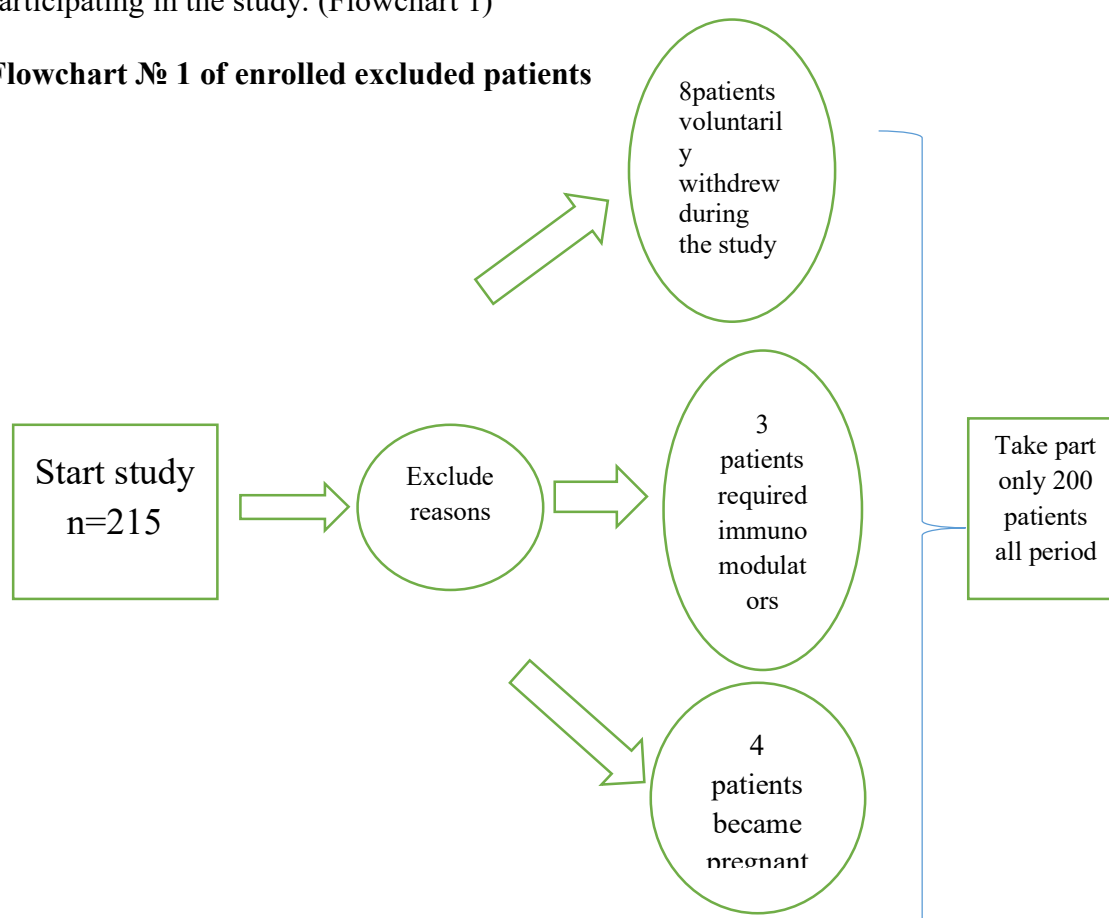
Purpose of the study. This clinical trial examined whether the incidence of recurring warts following laser therapy may be decreased by using laser therapy followed by Imiquimod 5% cream for 12 weeks.

Material and research methods.

Patients (n=200) were chosen from the university's laser dermato-venerology department. The main goal of the study was to analyze the efficacy and sustained clearance of anogenital warts following laser treatment as a monotherapy and combined therapy [laser+Imiquimod] as determined by clinical visual examination.

The trial was open to female patients with external anogenital warts aged 16 to 50. Patients were not eligible for the study if they had previously received Imiquimod, IFN, IFN-inducers, immunomodulators, oral antiviral medications (aside from oral acyclovir for suppressive or acute therapy), topical antiviral medications applied to the wart site, cytotoxic medications, other investigational medications, drugs known to have major organ toxicity, chemical and/or surgical wart therapy within four weeks of enrolling in the study, or any combination of these treatments (within two weeks of initiation visit). Also, patients with inflammatory skin disorders or those who required concurrent topical medication in the wart location were excluded, as were women who were expecting or nursing. 215 patients were enlisted at the start of the trial, but by the time it was over, only 200 remained. 15 patients were excluded for the following reasons: 8 patients voluntarily withdrew during the study; 3 patients required immunomodulators for acute illnesses; and 4 patients became pregnant while participating in the study. (Flowchart 1)

Flowchart № 1 of enrolled excluded patients



The patients were split into two groups to study the efficacy of the revised therapeutic strategy. Control group (I - n=75) women made up the first patient group, to whom we utilized the Lutronic CO2 laser technology for genital wart eradication. The technique enables layer-by-layer removal of

the tumor along with the underlying stroma, which is not possible with straightforward surgical excision. We performed continuous CO₂-laser vaporization of vulvar condylomas using the high-intensity laser surgical tool "Lutronic" with a radiation output of 16–20 W and a destruction depth of 0.3–0.7 cm.

The patients in both groups received wound care with Betadine solution 4–6 times starting on the first day following the damaging therapy, until a crust developed within 14 days.

The main group (II n=125) of patients included 125 women who had combination therapy with the 5% local cream "Imiquimod" after having their genital warts removed by laser. Starting on the fourteenth day following the destruction, the patients in the main group received a single application of the 5% cream "Imiquimod" in the amount of 3g per use on the affected area, nearby tissues, and the area around the anus. This treatment was given every other day for 12 hours for 4–12 weeks. After 1, 3, and 6 months after destruction, observations of patients were conducted, and it was noted that there had been no relapse or reinfection. We declared a clinical recovery based on the clinical evidence and the absence of new genital warts.

Table №. 1.

Some parameters of patients who participated in the study.

№	Patient Selection Criteria	Number of patients participating in the study (n=200)
1.	Sex	
	Women	100% (200)
2.	Age (16-50)	29,6±7,4
3.	Pregnancy	-
4.	HPV screening titer 12 types	
	HPV DNA A5A6 (types 51,56)	3
	HPV DNA A7 (types 18,39,45,59)	5
	HPV A9 DNA (types 16,31,33,35,52,58)	8
5	Number of partners	
	1	115
	2	47
	3 and more	38
6	Localization	
	In the area of the labia	70
	In the urethra, vagina and cervix	90
	in the perianal region	40
7	Clinical forms	
	Macular lesions	8
	Papular warts	23
	Condyloma acuminata	169

Regarding sex, age, and the severity of the diseased process, both patient groups were comparable. In our study, 200 individuals underwent laser ablation. The number of patients with no recurrence of vulvar genital warts during the 6-month follow-up period, as well as the significance of differences between groups in the frequency of genital wart recurrence using the Chi² test and Fisher's exact test, were used to evaluate the efficacy of the methods we used. The follow-up period was completed by 200 patients in total. We examined the frequency of vaginal wart recurrence in patients 6 months after the commencement of treatment in order to evaluate the efficacy of the prescribed treatment over the course of this study. The existence of at least one development in the region of the external genital organs was the requirement for recurrence.

Table № 2.

List of comorbid conditions

№	List of comorbid conditions	Group I n=75	Group II n=125
1	Anemia	57 (76%)	96 (76.8%)
2	Hypothyroidism	45 (60%)	82 (65.6%)
3	Diabetes	2 (2.7%)	1 (0.8%)
4	STD	69 (92%)	110 (88%)

RESULTS

Table № 3.

Comparative evaluation of clinical efficacy of treatment.

Following period	I group n-75		II group n-125		p
	abs.	%	abs.	%	
1 st month	12	16	6	4.8	p≤0.05
3 rd month	9	12	3	2.4	p≤0.05
6 th month	7	9.3	0	0	p≤0.05

In a comparative evaluation of the efficacy of treatment for external genital warts in the anogenital region for six months, it was determined that: after one month, the best clinical effect was detected when using a complex method of treatment; only six patients (4.8%) experienced new genital warts during examination and vulvoscopy, which was significantly less than the control group's twelve (16%) cases. In group I, 9 (12%) patients demonstrated an aggravation of the condition in the form of the formation of new clinical foci after a 3-month follow-up period, while group II had a recurrence rate of 3 (2.4%) during the same time frame. Seven (9.3%) of the group I patients experienced relapses at the conclusion of the observation period (6 months), whereas there was no relapse in the group II, demonstrating the efficacy of a complicated treatment regimen for genital warts. The presented data shows that the frequency of genital wart recurrence was statistically substantially ($p \leq 0.05$) lower with a complicated way of therapy than with laser monotherapy.

Table No. 3.

Total number of relapses during the observation period.

	I group n-75		II group n-125		p	Chi2	RR	95% CI(C)
	abs.	%	abs.	%				
Total number of relapses	28	37.3	9	7.2%	p≤0,001	28.23 0	2.624	1.939 - 3.552
Absence of relapse	47	62.7	116	94.4				

According to the study, sophisticated methods of therapy are a rather successful way to cure external genital warts in the anogenital region. A comparison of the clinical efficacy of the treatments revealed that 28 (37.3%) of the first group's patients experienced relapses throughout the entire observation period. The recurrence rate within 6 months was only 9 (7.2%) and clinical recovery without a recurrence was 116 (92.8%) in group II patients, which is a statistically significant ($p \leq 0.05$) reduction in the relapse rate with the complex method therapy.

There were no documented severe adverse medication reactions. A few instances of systemic symptoms like fever or myalgia were observed, although local skin reactions at the treatment site were the most often reported adverse event. The most frequent side effects, which affected more than 80% of all patients, were skin diseases in the areas where the warts were treated, including burning, itching, pain, and redness. Generally, they were easily tolerated and went away quickly once the dosage was lowered or a break was taken.

Discussion.

With the complicated method therapy, there was a statistically significant ($p \leq 0.05$) decrease in the relapse rate, with the recurrence rate within 6 months being only 9 (7.2%) and clinical recovery without a recurrence being 116 (92.8%) in group II patients.

More than 80% of patients had skin conditions, including burning, itching, soreness, and redness, in the locations where the warts were treated, as the most common side effects. In general, they were well tolerated and promptly subsided if the dosage was reduced or a break was taken.

Recurrence rates after laser therapy for genital warts are vary, according to data from the literature, and they tend to happen more often around the edges of previously ablated areas. It has been suggested that the outcome could be enhanced by extending the ablation to surrounding, clinically unaffected regions that carry latent HPV beyond the apparent lesion [11]. Immune response modifiers allow for an alternative strategy by improving the cutaneous antiviral immune response. The outcomes of this open-label, prospective study show that Imiquimod 5% cream, an adjuvant topical immunomodulatory medication, can prolong the effects of laser therapy for external genital warts. In this study, laser therapy combined with Imiquimod 5% cream produced better benefits than laser therapy alone as reported in the literature [7,14].

According to the literatures local cellular immune response is activated by adjuvant Imiquimod 5% cream treatment, and this response is principally mediated by the stimulation of specific pro-inflammatory and antiviral cytokines, primarily IFN- α , tumor necrosis factor- α (TNF- α), and various interleukines (e.g., IL-6, -8, -10, -12). A molecular investigation with HPV-infected patients has shown the mechanism of action in HPV-related genital warts [7]. Changes in the tissue levels of these cytokines and a considerable drop in viral load, as indicated by tissue levels of E7-mRNA and capsid protein L1-mRNA, were directly associated with wart regression. Most intriguingly, one trial participant who received placebo also completely cleared his warts, and the alterations in immunological markers that were observed in this participant were very identical to those in the patients who received Imiquimod. Similar to the immunological process that takes place during spontaneous regression, this improvement in the local immune response also has a long-term effect on cutaneous HPV-infections, preventing recurrences and new infections with the same HPV type or subtype [12].

It is known from earlier research that Imiquimod 5% cream causes local skin reactions often, especially during the first month of treatment. These reactions are thought to be caused by local immune induction and are a crucial component of the medication's antiviral and anticancer activities [7–9]. In this study, Imiquimod 5% cream was used after laser therapy, and the first month of treatment was when skin responses were most common. The process of wound healing itself is connected to particular changes in skin immunology. It has been shown that over the 42 days following surgery.

Simple study design is one of the strengths of this descriptive type of the research.

Weaknesses of the study are single center study, Pamirid race, uzbek nation and small size of sample.

Conclusion.

The results of this study clearly show that topical Imiquimod 5% cream treatment for 12 weeks after laser treatment of genital warts is safe and appears to be an effective therapeutic approach to reduce the incidence of wart recurrences, which is one of the least desirable aspects of conventional treatment modalities.

Using a combined approach to treat genital warts is a better technique of treatment since it allows for deeper penetration of the local 5% Imiquimod cream, which is where this medication's

immunomodulatory properties are active, by reducing hyperkeratosis through laser vaporization. In turn, this cream affects the lesion's site-specific clinical and subclinical HPV forms, which cannot be treated by laser light. This result implies that these two approaches complement one another and lower the recurrence rate.

References.

1. Woodby B, Scott M, Bodily J. The Interaction Between Human Papillomaviruses and the Stromal Microenvironment. *Progress in Molecular Biology and Translational Science*. 2016; 144:169-238. DOI: <https://doi.org/10.1016/bs.pmbts.2016.09.003>
2. Xiao Yang, Yanxiang Cheng, Chunsheng Li. The role of TLRs in cervical cancer with HPV infection: a review. *Signal Transduction and Targeted Therapy* 2017; 2: e17055. DOI: 10.1038/sigtrans.2017.55
3. Xu H, Shen Q, Fan B, Xi C, a combination therapy of traditional Chinese medicine and CO laser treatment for condyloma acuminatum. *Journal of medical virology*. 2020. Online ahead of print.
4. Yuan H, Krawczyk E, Blancato J, Albanese C, Zhou D, Wang N, et al. HPV positive neuroendocrine cervical cancer cells are dependent on Myc but not E6/E7 viral oncogenes. *Scientific Reports*. 2017; 7:45617.
5. Zeng Y, Hesketh T. The effects of China's universal two-child policy. *Lancet*. 2016; 388:1930-1938.
6. Zeng Y.Y, Chen XY, Tian KG, et al. The correlation of interleukin-10 gene polymorphism and HPV infection and cervical lesions in Dongguan region. *Journal of Clinical and Experimental Medicine*. 2015; 14:636-639.
7. Yring SK, Arany I, Stanley MA, et al. A randomized, controlled, molecular study of condylomata acuminata clearance during treatment with imiquimod. *J Infect Dis* 1998; 178:551-5
8. Westrich JA, Warren CJ, Pyeon D. Evasion of host immune defenses by human papillomavirus. *Virus research*. 2017; 231:21-33.
9. Wiraguna AAGP, Andriani PI, Adiguna MS. Comparison of Plasma Zinc Levels Among HIV+ and HIV- Subjects Infected with Condyloma Acuminata. *Asian Pac J Cancer Prev*. 2019;20(3):943-949. Published 2019 Mar 26. doi:10.31557/APJCP.2019.20.3.943
10. Wojcinski M. 14 Jahre HPV-Impfung: was haben wir erreicht? [14 years of HPV vaccination: what has been achieved?]. *Gynakologe*. 2021;54(11):801-809. doi:10.1007/s00129-021-04869-3
11. Ferenczy A, Mitao M, Nagai N, et al. Latent papillomavirus and recurrent genital warts. *N Engl J Med* 1985; 313:784-8
12. Riva JM, Sedlacek T, Cunnane MF, Mangan CE. Extended carbon dioxide laser vaporization in the treatment of subclinical papillomavirus infection of the lower genital tract. *Obstet Gynecol* 1989;73: 25-30

ЎЗБЕК ТИББИЁТ ЖУРНАЛИ

1 МАХСУС СОН

ЎЗБЕКСКИЙ МЕДИЦИНСКИЙ ЖУРНАЛ
СПЕЦИАЛЬНЫЙ НОМЕР 1

UZBEK MEDICAL JOURNAL
SPECIAL ISSUE 1

Editorial staff of the journals of www.tadqiqot.uz
Tadqiqot LLC the city of Tashkent,
Amir Temur Street pr.1, House 2.
Web: <http://www.tadqiqot.uz/>; Email: info@tadqiqot.uz
Phone: (+998-94) 404-0000

Контакт редакций журналов. www.tadqiqot.uz
ООО Тадқиқот город Ташкент,
улица Амира Темура пр.1, дом-2.
Web: <http://www.tadqiqot.uz/>; Email: info@tadqiqot.uz
Тел: (+998-94) 404-0000